



HAL
open science

Calcinosis cutis in epidermal necrolysis: role of caspofungin?

H. Colboc, T. Bettuzzi, M. Badrignans, D. Bazin, A. Boury, E. Letavernier, V. Frochot, E. Tang, P. Moguelet, N. Ortonne, et al.

► To cite this version:

H. Colboc, T. Bettuzzi, M. Badrignans, D. Bazin, A. Boury, et al.. Calcinosis cutis in epidermal necrolysis: role of caspofungin?. *Journal of the European Academy of Dermatology and Venereology*, 2022, 130 (4), pp.214 - 223. 10.1111/jdv.17808 . hal-04128660v2

HAL Id: hal-04128660

<https://universite-paris-saclay.hal.science/hal-04128660v2>

Submitted on 14 Jun 2023

HAL is a multi-disciplinary open access archive for the deposit and dissemination of scientific research documents, whether they are published or not. The documents may come from teaching and research institutions in France or abroad, or from public or private research centers.

L'archive ouverte pluridisciplinaire **HAL**, est destinée au dépôt et à la diffusion de documents scientifiques de niveau recherche, publiés ou non, émanant des établissements d'enseignement et de recherche français ou étrangers, des laboratoires publics ou privés.

Author Query Form

Journal: JDV

Article: 17808

Dear Author,

During the copyediting of your manuscript the following queries arose.

Please refer to the query reference callout numbers in the page proofs and respond.

Please remember illegible or unclear comments and corrections may delay publication.

Many thanks for your assistance.

AUTHOR: Please note that missing content in references have been updated where we have been able to match the missing elements without ambiguity against a standard citation database, to meet the reference style requirements of the journal. It is your responsibility to check and ensure that all listed references are complete and accurate.

Query reference	Query	Remarks
1	AUTHOR: Please note that no additional changes will be accepted after your corrections are submitted.	
2	AUTHOR: Please confirm that given names (blue) and surnames/family names (vermilion) have been identified correctly.	
3	AUTHOR: Please verify that the linked ORCID identifiers are correct for each author.	
4	AUTHOR: Please check that authors and their affiliations are correct.	
5	AUTHOR: Please note that no additional changes will be accepted after your corrections are submitted.	

LETTER TO THE EDITOR

Calcinosis cutis in epidermal necrolysis: role of caspofungin?

Dear Editor,

Toxic epidermal necrolysis (TEN) is a rare life-threatening condition, usually drug-induced, characterized by a diffuse epidermal and mucosal detachment. Skin histology reveals pan epidermal necrolysis. Mucocutaneous healing usually lasts 2–3 weeks.¹ Calcinosis cutis is reported in various skin diseases, with dystrophic calcification following tissue damage being its most common cause.² We describe four patients who presented TEN and atypical healing retardation due to calcinosis cutis.

Between 2015 and September 2021, four patients, three males and one female, aged from 40 to 59 years old, were diagnosed with TEN, idiopathic or following intake of ibuprofen, pantoprazole and allopurinol respectively. Three to 22 days following the beginning of cutaneous healing, they presented a secondary cutaneous detachment with atone fibrinous plaques (Fig. 1). A new biopsy revealed in the four cases calcium deposition in the superficial dermis and in the epidermis (Fig. 2a). Ionized serum calcium and phosphate levels were normal. One patient died without healing, whereas complete healing was slowly obtained within 5.5 and 11 months for two patients, and is still ongoing for one.

To investigate the origin of these cutaneous calcifications, osteogenic markers, assessed by immunohistochemistry were

performed in three patients. Results were negative on keratinocytes and fibroblasts, making unlikely trans-differentiation of these cells to an osteochondrogenic phenotype, a mechanism frequently suspected in calciphylaxis.³ μ Fourier transform infra-red spectroscopy revealed that calcifications consisted of apatite, a classic component of dystrophic skin calcifications observed in other diseases.^{2,4} Field emission scanning electron microscopy revealed that the ultrastructure of these skin calcifications consisted of small spherical entities of 500 nm aggregating into voluminous plaques (Fig. 2b–d), as previously described in other ectopic calcifications.⁵ These spherical entities were also identified within the papillary dermis (Fig. 2e,f). Calcium-phosphate nature of these entities was confirmed by energy dispersive X-ray spectroscopy.

Reviewing the medical chart, we found that the four patients were treated with caspofungin for invasive fungal infection to *Candida parapsilosis*, *Candida lusitanae*, *Candida albicans* or non-documented septic shock 1–8 days before the secondary epidermal detachment. Among the 130 patients with Stevens–Johnson syndrome or TEN referred in our centre between 2015 and 2021, four other patients with TEN received caspofungin: three died in the following days without any dermatological examination. In the fourth case, new fibrinous plaques were described in the medical chart 4 days later, without imaging or histology performed.

We report herein four patients with TEN exhibiting calcinosis cutis after caspofungin administration. Caspofungin is an

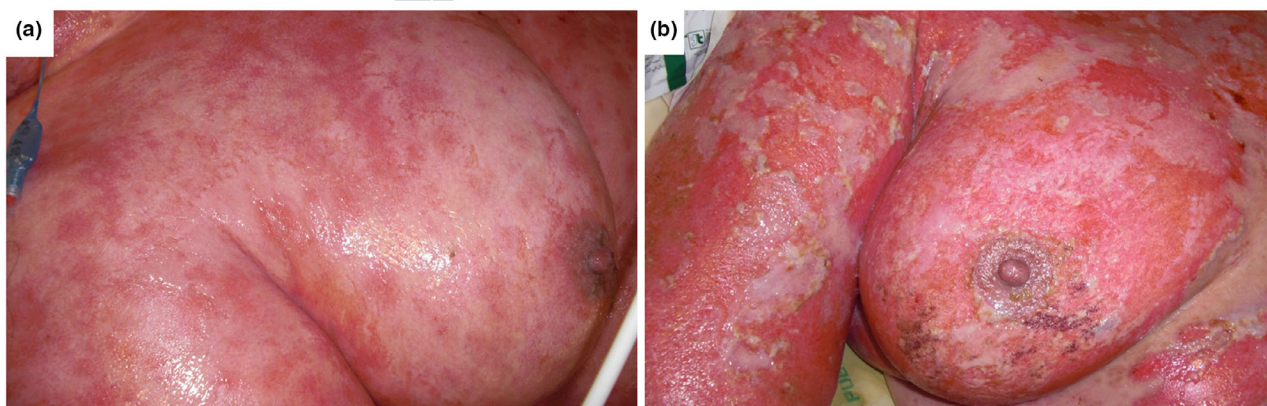


Figure 1 Clinical presentation of one patient. (a) Dermatological examination on day 12, revealing almost complete mucocutaneous healing. (b) Dermatological examination on day 29, 11 days after the introduction of caspofungin, revealing diffuse epidermal detachment associated with the presence of fibrinous plaques.

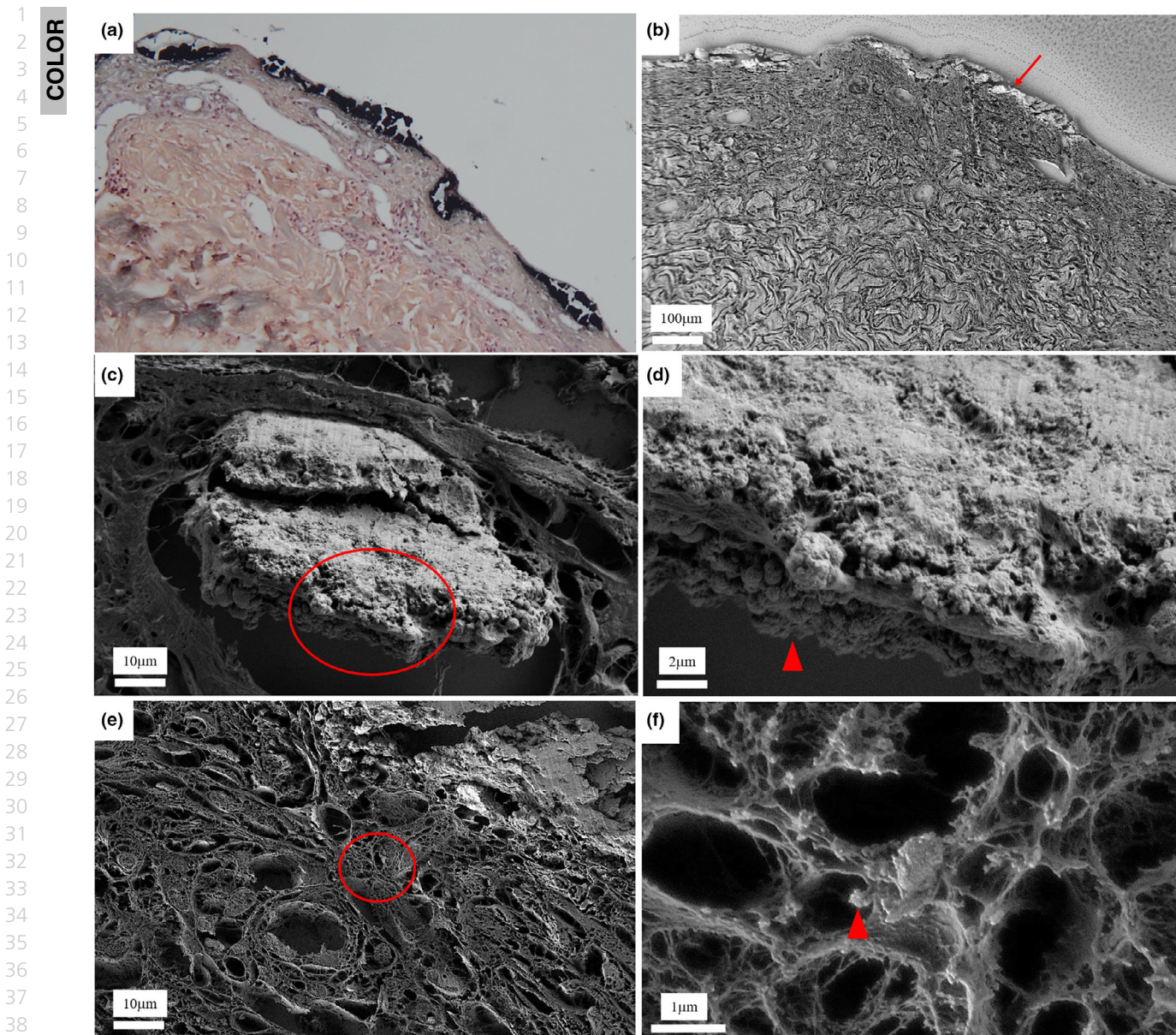


Figure 2 Skin biopsy sections. Diffuse necrosis of the corneal layer associated with calcium deposition in the superficial dermis. (a) Von Kossa staining ($\times 100$). (b) Field emission scanning electron microscopy. Arrow indicates the voluminous calcifications. (c–f) Field emission scanning electron microscopy. (c) The lower part of the voluminous calcification (circle) consists of many small aggregated spherical entities. (d) High magnification of panel (c) circled area. (e) Papillary dermis below voluminous calcification. (f) High magnification of panel (e) circled area, showing many spherical calcifications within the papillary dermis.

agonist of ryanodine receptor (RyR).^{6,7} RyR is strongly expressed in keratinocytes and application of RyR's agonist induced intracellular calcium flux, leading to delayed cutaneous healing in a mouse model.⁸ By modifying keratinocytes' calcium intracellular concentration, caspofungin might have altered the new keratinocytes at the very initial stage of cutaneous healing, explaining the

presence of upper dermis and epidermal calcifications and the relapse of epidermal detachment followed by a major healing retardation.

Calcifications were small spherical entities aggregated into voluminous plaques contiguous to the epidermal necrosis, made of apatite, and were not caused by trans-differentiation of the

skin cells into an osteochondrogenic phenotype. Presence of calcified entities within the upper but not the deeper dermis suggests a link between local inflammation induced by TEN and calcifications, as observed in other dystrophic calcified skin diseases. Skin calcifications have also been described in other diseases associated with diffuse epidermal detachment, such as porphyria cutanea tarda and dystrophic epidermolysis bullosa.^{9,10}

Liposomal amphotericin B or fluconazole might, therefore, be preferred for these patients in case of invasive fungal infection. Further studies regarding dermatological adverse events induced by caspofungin, especially on mucocutaneous healing, should be performed.

Acknowledgements

The patients in this study have given written informed consent to publication of their case details.

Conflict of interest

All authors have any conflicts of interest to declare.

Funding sources

None declared.

Data Availability Statement

Derived data supporting the findings of this study are available from the corresponding author on reasonable request.

H. Colboc,^{1,2,*†} T. Bettuzzi,^{3,4,5,†} M. Badrignans,⁶
D. Bazin,⁷ A. Boury,⁷ E. Letavernier,^{2,8} V. Frochet,^{2,8}
E. Tang,² P. Moguelet,⁹ N. Ortonne,⁵ N. de Prost,¹⁰
S. Ingen-Housz-Oro^{3,4,5}

¹Service Plaies et Cicatrisation, Sorbonne Université, Hôpital Rothschild, Paris, France, ²UMR_S 1155, Sorbonne Université-UPMC Paris 06, Paris, France, ³Service de Dermatologie, Hôpital Henri Mondor, Assistance Publique Hôpitaux de Paris, Créteil, France, ⁴Univ Paris Est Créteil, EpiDermE, Créteil, France, ⁵Reference Center for Toxic Bullous Dermatoses and Severe Drug Reactions TOXIBUL, Créteil, France,

⁶Service de Pathologie, Hôpital Henri Mondor, Assistance Publique Hôpitaux de Paris, Créteil, France, ⁷CNRS, IPC, Ba340, Université Paris XI, Orsay, France, ⁸Service des Explorations Fonctionnelles Multidisciplinaires, Sorbonne Université, Hôpital Tenon, Paris, France, ⁹Service de Pathologie, Sorbonne Université, Hôpital Tenon, Paris, France, ¹⁰Service de Réanimation Médicale, Hôpital Henri Mondor, Assistance Publique Hôpitaux de Paris, Créteil, France

*Correspondence: H. Colboc. E-mail: hester.colboc@aphp.fr

†These authors equally contributed to this work.

References

- Ingen-Housz-Oro S, Duong T-A et al. Epidermal necrolysis French national diagnosis and care protocol (PNDS; protocole national de diagnostic et de soins). *Orphanet J Rare Dis* 2018; **13**: 56.
- Reiter N, El-Shabrawi L, Leinweber B, Berghold A, Aberer E. Calcinosi cutis. *J Am Acad Dermatol* 2011; **65**: 15–22.
- Nigwekar SU, Thadhani R, Brandenburg VM. Calciphylaxis. *N Engl J Med* 2018; **378**: 1704–1714
- Carden A, Morris MD. Application of vibrational spectroscopy to the study of mineralized tissues. *J Biomed Opt* 2000; **5**: 259–268.
- Lakhdar AB, Daudon M, Mathieu MC, Kellum A, Balleyguier C, Bazin D. Underlining the complexity of the structural and chemical characteristics of ectopic calcifications in breast tissues through FE-SEM and μ FTIR spectroscopy. *CR Chim* 2016; **19**: 1610–1624.
- Müller S, Koch C, Weiterer S, Weigand MA, Sander M, Henrich M. Caspofungin induces the release of Ca^{2+} ions from internal stores by activating ryanodine receptor-dependent pathways in human tracheal epithelial cells. *Sci Rep* 2020; **10**: 11723.
- Koch C, Jersch J, Schneck E et al. Caspofungin modulates ryanodine receptor-mediated calcium release in human cardiac myocytes. *Antimicrob Agents Chemother* 2018; **62**: e01114–e1118.
- Denda S, Kumamoto J, Takei K, Tsutsumi M, Aoki H, Denda M. Ryanodine receptors are expressed in epidermal keratinocytes and associated with keratinocyte differentiation and epidermal permeability barrier homeostasis. *J Invest Dermatol* 2012; **132**: 69–75.
- Rey J, Hesse S, Bonerandi JJ. Extensive calcifications of the scalp in a patient with porphyria cutanea tarda secondary to hepatitis C virus infection. *J Eur Acad Dermatol Venereol* 2007; **21**: 286–287.
- Bhari N, Bharti P. Dystrophic calcinosis cutis in autosomal recessive dystrophic epidermolysis bullosa. *BMJ Case Rep* 2019; **12**: e231287.

DOI: 10.1111/jdv.17808