



HAL
open science

Apoplexy of microprolactinomas during pregnancy: report of five cases and review of the literature

Emmanuelle Kuhn, Alexandra Weinreich, Nienke Biermasz, Jens Otto L
Jorgensen, Philippe Chanson

► **To cite this version:**

Emmanuelle Kuhn, Alexandra Weinreich, Nienke Biermasz, Jens Otto L Jorgensen, Philippe Chanson.
Apoplexy of microprolactinomas during pregnancy: report of five cases and review of the literature.
European Journal of Endocrinology, 2021, 185 (1), pp.99-108. 10.1530/EJE-21-0145 . hal-04323497

HAL Id: hal-04323497

<https://universite-paris-saclay.hal.science/hal-04323497>

Submitted on 11 May 2024

HAL is a multi-disciplinary open access archive for the deposit and dissemination of scientific research documents, whether they are published or not. The documents may come from teaching and research institutions in France or abroad, or from public or private research centers.

L'archive ouverte pluridisciplinaire **HAL**, est destinée au dépôt et à la diffusion de documents scientifiques de niveau recherche, publiés ou non, émanant des établissements d'enseignement et de recherche français ou étrangers, des laboratoires publics ou privés.

Apoplexy of microprolactinomas during pregnancy: report of five cases and review of the literature

Emmanuelle Kuhn^{1,*}, Alexandra A Weinreich^{2,*}, Nienke R Biermasz³, Jens Otto L Jorgensen² and Philippe Chanson¹

¹Université Paris-Saclay, Inserm, Physiologie et Physiopathologie Endocriniennes, Assistance Publique-Hôpitaux de Paris, Hôpital Bicêtre, Service d'Endocrinologie et des Maladies de la Reproduction, and Centre de Référence des Maladies Rares de l'Hypophyse, Le Kremlin-Bicêtre, France, ²Department of Endocrinology and Internal Medicine, Aarhus University Hospital, Medical Research Laboratory, Aarhus University, Aarhus, Denmark, and ³Division of Endocrinology, Department of Medicine, Pituitary Center and Center for Endocrine Tumors, Leiden University Medical Center, Leiden, The Netherlands

*(E Kuhn and A A Weinreich contributed equally to this work)

Correspondence should be addressed to J O L Jorgensen or P Chanson

Email

joj@clin.au.dk or philippe.chanson@bct.aphp.fr

Abstract

Context: Prolactinomas frequently cause amenorrhoea, galactorrhoea and infertility and require dopamine agonist (DA) treatment to normalize prolactin levels and hence, restore ovulation. The vast majority of female patients harbour microprolactinomas in whom DA treatment is usually discontinued at the time of pregnancy diagnosis and surveillance is generally limited as the symptomatic growth is considered very rare.

Case descriptions: We report five cases of women harbouring a microprolactinoma in whom symptomatic pituitary apoplexy occurred during pregnancy. Only one necessitated surgery during pregnancy, while the others were treated conservatively by reintroducing DAs in three. A systematic literature review found reports of four additional cases among 20 cases of prolactinomas (both macro- and micro-prolactinomas) complicated by apoplexy during pregnancy.

Conclusion: During pregnancy, pituitary apoplexy may occur in pre-existing microprolactinomas, causing tumour enlargement and headache, which may be self-limiting but may require intervention by re-initiation of dopamine agonists or surgery. Our literature review confirms that this clinical event is rare; nevertheless, physicians managing pregnant patients with microprolactinomas must be aware that symptomatic pituitary apoplexy may incidentally occur in all trimesters of pregnancy and require prompt radiological, endocrine and ophthalmological assessment and treatment.

European Journal of
Endocrinology
(2021) **185**, 99–108

Introduction

Prolactinomas represent the most common type of hormone-secreting adenomas, accounting for approximately 50% of all pituitary tumours requiring medical attention (1, 2). Most women with prolactinoma harbour a microadenoma; therefore, endocrine symptoms are much more prevalent than mass effects, in particular, in the reproductive age. Classic symptoms of prolactinomas in women include oligo- or amenorrhoea

(which is present in 85–90%), galactorrhoea (present in 84%) (3) and infertility (3, 4, 5, 6). To restore fertility, women with hyperprolactinaemia who wish to become pregnant are frequently offered dopamine agonist (DA) treatment, which successfully restores ovulation in over 90% of patients (7). It is recommended to discontinue DAs upon confirmation of pregnancy due to the very low risk of growth of microprolactinomas (8). According to a

recent review, 2.5% of microprolactinomas are reported to grow during pregnancy but this growth is minimal, with the maximal diameter of the adenoma generally not exceeding 10 mm. Pituitary apoplexy (PA) appears to be a very rare event in such a condition. PA is an acute clinical syndrome due to tumour infarction or haemorrhage causing an abrupt and transient tumour enlargement. It is characterized by sudden onset of headache, nausea, vomiting, visual disturbance, ophthalmoplegia and decreased consciousness and new-onset hypopituitarism (9). Between 2 and 12% of patients with all types of adenoma experience apoplexy (9). Precipitating factors, such as angiographic procedures (particularly cerebral), surgery (orthopaedic and cardiac), head trauma, dynamic endocrine testing or treatment with releasing hormones, have been described (9). PA is a rare entity during pregnancy (10, 11, 12). Here, we report five cases of microprolactinoma apoplexy during pregnancy and review the literature about this topic.

Methods

For the literature review, only published studies in English were eligible. The search was conducted using PRISMA guidelines. The search words were « ((pituitary apoplexy) OR 'Pituitary Apoplexy'(MeSH)) AND 'Pregnancy'(MeSH), '("Prolactinoma"(MeSH)) AND "Pregnancy"(MeSH), '(prolactinoma) AND "pituitary apoplexy", "(prolactinoma) AND "pituitary apoplexy") AND "Pregnancy"(MeSH) ». The cases included in this systematic review were patients experiencing symptomatic gestational PA in a prolactinoma. The criteria 'microprolactinom' was fulfilled if the patient was diagnosed with a prolactinoma whose diameter was below 1 cm. The criterion 'pituitary apoplexy' was fulfilled if the authors claimed that the patient suffered from this condition.

The study did not require approval by an ethical or institutional review board in either country; however, formal approval was obtained from each patient, and data handling was performed according to national laws.

Cases presentation

Case 1

In 2012, a microprolactinoma (7 mm) (Fig. 1A) was diagnosed in a 31-year-old woman referred to the Department of Endocrinology with secondary

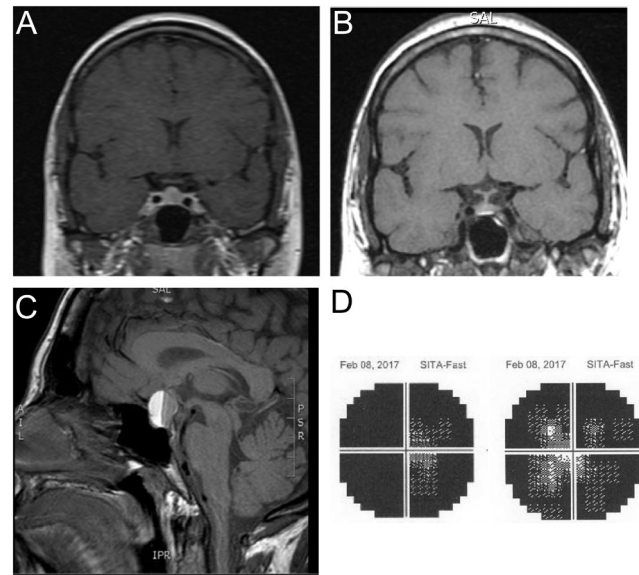


Figure 1

Course of pituitary MRI and visual field in case 1. (A) MRI T1-W, post-gadolinium coronal view performed at diagnosis; (B) MRI T1-W, post-gadolinium coronal view after cabergoline treatment and the first pregnancy (before the second pregnancy); (C) T1-W sagittal view of apoplectic pituitary adenoma; (D) octopus perimetry revealed pronounced bitemporal hemianopia.

amenorrhoea and galactorrhoea. The initial serum PRL level was 149 µg/L. Medical treatment with cabergoline at a dose of 0.5 mg/week rapidly provided symptom relief and normalized the serum prolactin levels. The patient became pregnant in 2014 during which cabergoline was discontinued and followed by an uneventful spontaneous delivery and breastfeeding. A second pituitary MRI in 2015 revealed a regression of the adenoma (maximal diameter 3–4 mm) (Fig. 1B), the serum prolactin level was normal (17 µg/L). In 2016, the patient became pregnant again and discontinued cabergoline. At gestational week 36, the patient developed acute-onset visual impairment, headache and photophobia. A subsequent MRI showed signs of bleeding and tumour enlargement and was diagnosed as PA (Fig. 1C). Octopus perimetry revealed pronounced bitemporal hemianopia (Fig. 1D), and cabergoline treatment was promptly restarted. However, in the absence of distinct improvement of visual function after 2 days of cabergoline treatment, the patient underwent transsphenoidal surgery, which provided immediate symptom relief and normalization of visual function. Thirty days after TSS, the patient delivered a healthy baby by planned Caesarean section.

Case 2

A 21-year-old woman presented with secondary amenorrhoea and galactorrhoea after interruption of her oral contraception in October 1999. Her serum PRL level was elevated at 80 µg/L. A CT scan detected a microadenoma (7 mm diameter) in the left side of the pituitary (Fig. 2A). She was treated successfully with bromocriptine 5 mg per day, leading to the resumption of regular menses. Four months later, the patient became pregnant and discontinued the DA treatment. At 26 weeks of gestation, she developed fatigue, transient polyuria and polydipsia (5 L per day). Laboratory work-up revealed unexpected corticotropic and thyrotrophic deficiencies. As an ophthalmologic evaluation, including perimetry, was normal, it was decided not to perform MRI. She was replaced with oral hydrocortisone, L-thyroxine, and desmopressin. She gave birth to a healthy girl by the vaginal route. A post-partum MRI revealed tumour volume increase, with a 2 cm adenoma with signs of bleeding (Fig. 2B, C and D). The patient's hypopituitarism persisted postpartum,

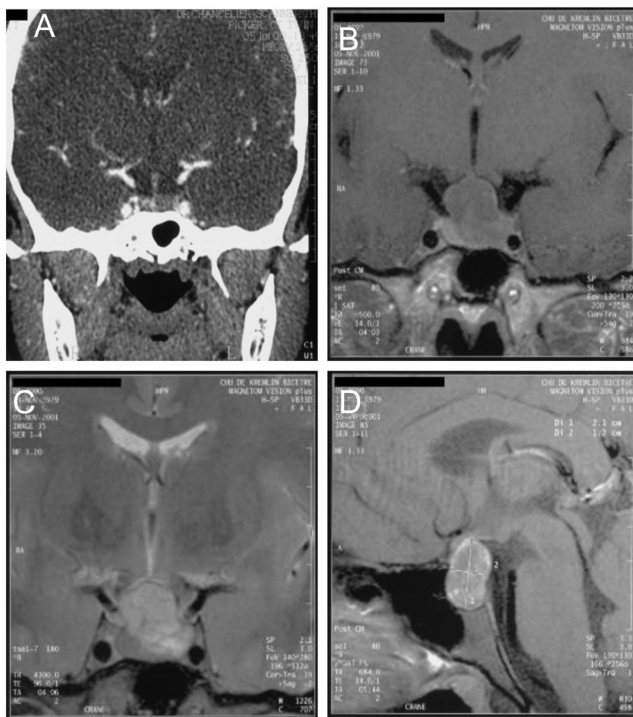


Figure 2

Course of pituitary CT scan and MRI in case 2. (A) CT scan before pregnancy showing the microprolactinoma (coronal view); (B) MRI T1-W, post-gadolinium coronal view; (C) T2-W coronal view; (D) T1-W post-gadolinium sagittal view of apoplectic pituitary adenoma after delivery.

and the serum PRL levels had increased to 235 µg/L. The patient underwent TSS, which revealed a pituitary lesion with evidence of necrosis and haemorrhage, with positive immunostaining for PRL. At follow-up, ACTH and TSH secretion spontaneously normalized, whereas diabetes insipidus and hyperprolactinaemia persisted. The patient was treated with DA and desmopressin.

Case 3

A 32-year-old pregnant woman with a microprolactinoma was referred for visual loss in the left eye at the 35th gestational week of her third pregnancy. Four years before, hyperprolactinaemia was diagnosed, together with secondary amenorrhoea and galactorrhoea. At diagnosis, the serum PRL level was increased to 240 µg/L. MRI detected a large microadenoma (10 mm diameter) in the left part of the pituitary gland (Fig. 3A and B). She was treated with cabergoline of 0.5 mg/week. She experienced two uneventful pregnancies and deliveries initiated under cabergoline treatment and interrupted cabergoline as soon as she knew she was pregnant in both cases. She became pregnant for the third time, interrupted

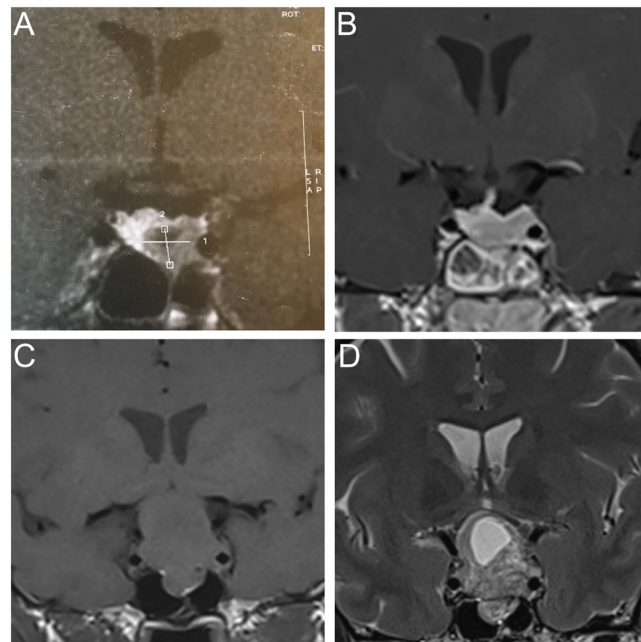


Figure 3

Course of pituitary MRI in case 3. (A and B) MRI T1-W, post-gadolinium coronal views performed before pregnancy; (C) MRI T1-W; (D) T2-W coronal views of apoplectic pituitary adenoma during pregnancy.

cabergoline treatment and developed headache and vision loss in the left eye at gestational week 33. MRI showed signs of bleeding in the adenoma, which had increased in size (30 × 24 mm), leading to the diagnosis of PA with compression of the optic chiasm (Fig. 3C and D). Cabergoline was resumed (1 mg/week) and hydrocortisone (20 mg/day) was added. Headache rapidly disappeared and visual acuity improved. She gave birth to a healthy girl by vaginal delivery. DA treatment was continued, and she did not nurse her baby. One month postpartum, corticotrophic deficiency persisted and the serum PRL level was normal under cabergoline.

Case 4

A 23-year-old woman, with a history of type 1 diabetes mellitus, presented with secondary amenorrhoea and hyperprolactinaemia (160 µg/L) and a small right-sided microadenoma of 5 mm (Fig. 4A). She was treated with cabergoline of 0.5 mg weekly. After treatment for 6 months, she became pregnant, and cabergoline was discontinued. Early in the second trimester, at 16 weeks gestation, she was seen in the emergency department because of the sudden onset of unbearable headaches. Her prolactin level at presentation was 200 ng/mL. This was considered compatible with the pregnancy stage and her known microprolactinoma. MRI without contrast revealed an increase in the pituitary mass, with suprasellar extension, difficult demarcation of tumour and pituitary, and contact with the optic chiasm (Fig. 4B). An ophthalmologic evaluation revealed right quadrantanopia (MD -8.04) with extension to the inferonasal field compatible with chiasmatal compression but no clearly impaired visual acuity (ODS 1.2). Taking into account that the patient had side effects during the first course of DA treatment, watchful waiting without DA treatment was initially decided. Visual field was spontaneously improved and adenoma size was decreased on MRI performed 1 month later confirming pituitary

apoplexy. Due to persistent headaches, cabergoline was secondarily reinitiated at a dose of 0.25 mg/week. Her visual field defects improved gradually with complete normalization at week 26 of pregnancy while cabergoline 0.25 twice weekly was continued, and her vision improved to ODS 1.5/1.5. PRL levels were approximately 100 µg/L throughout pregnancy. There was no evidence of pituitary dysfunction. At 38 weeks, she delivered by caesarean section. Postpartum, she discontinued cabergoline without problems and was able to breastfeed. MRI performed 3 months after delivery showed that the microprolactinoma had returned to its previous size (Fig. 4C). Thereafter, she opted for surgical removal of her microprolactinoma due to drug intolerance and fear of becoming pregnant again with a risk of recurrence of microprolactinoma apoplexy.

Case 5

This 25-year-old woman had a history of severe headache and apoplexy in a newly diagnosed pituitary microadenoma (Fig. 5A) treated with a conservative approach 4 years previously, with no pituitary deficits but still hyperprolactinaemia. Two years after apoplexy, MRI revealed a microadenoma (Fig. 5B). She became pregnant after a short course of cabergoline. At mid-pregnancy, she had a new episode of severe headache, and a non-contrast MRI revealed the recurrence of apoplexy (Fig. 5C), which was treated conservatively. Two months later, she delivered spontaneously without complications but her menstrual cycle did not resume and she did not breastfeed. Postpartum, MRI showed the regression of the apoplectic adenoma (Fig. 5D). One year after delivery, she underwent transsphenoidal surgery and the remnant prolactinoma was removed. The pathology revealed prolactin immunostaining. Prolactin levels normalized thereafter but gradually increased, indicating recurrent disease.

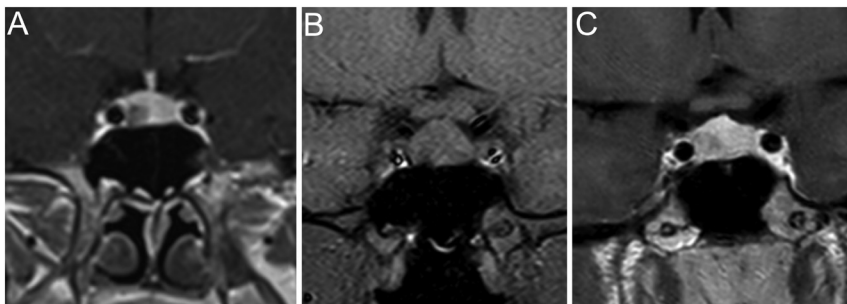
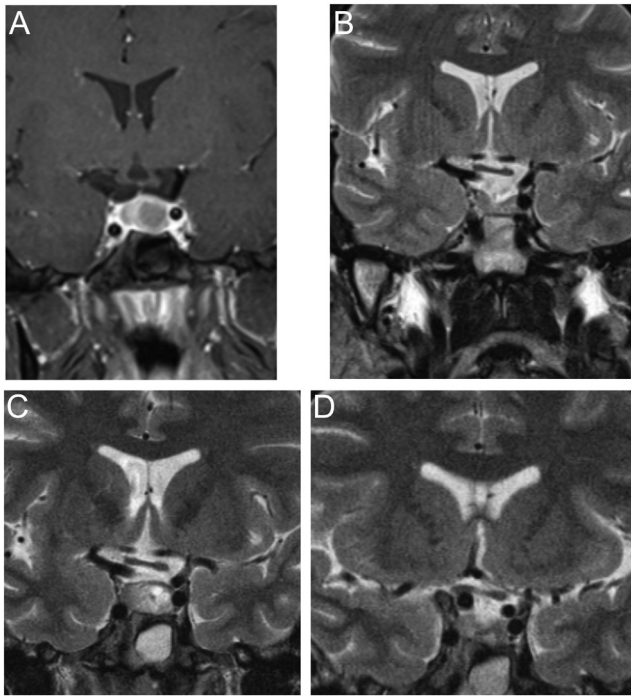


Figure 4

Course of MRI in case 4. (A) MRI T1-W, post-gadolinium coronal view performed at diagnosis, before pregnancy; (B) MRI T1-W coronal view of apoplectic pituitary adenoma during pregnancy; (C) MRI T1-W, post-gadolinium coronal view performed 3 months after delivery.

**Figure 5**

Course of MRI in case 5. (A) MRI T1-W, post-gadolinium coronal view performed at diagnosis; (B) MRI T2-W coronal view performed before pregnancy; (C) MRI T2-W coronal view of apoplectic pituitary adenoma during pregnancy; (D) MRI T2-W coronal view performed after delivery.

Literature review

In the literature, a total of 20 cases of prolactinoma apoplexy occurring during pregnancy have been reported (11, 13, 14, 15, 16, 17, 18, 19, 20, 21, 22, 23, 24, 25, 26, 27, 28, 29) (Table 1). Before pregnancy, 12 patients were diagnosed with macroadenomas and only 4 patients previously reported cases had been previously diagnosed with a microprolactinoma. In four cases, the adenoma size is not provided in the publication. DAs were discontinued at the diagnosis of pregnancy in all the cases. Headache had been reported as the presenting symptom in the majority of PA cases (88%), whether macro- or microprolactinomas. Three out of the four microprolactinomas had visual disturbance. Half of the prolactinomas, whether microprolactinomas or not, were managed conservatively, with DA therapy and hormone replacement when necessary. In the other half of patients, surgery was performed. Healthy babies were born at normal term in most of the cases. Endocrine insufficiencies persisted in three cases and diabetes insipidus persisted in two cases.

Discussion

We describe the rare occurrence of PA during pregnancy in five patients with microprolactinomas which add up to four cases reported in the literature (26, 27, 28, 29). Medical treatment and watchful waiting were chosen in four cases of our series while only one patient underwent TSS during pregnancy. TTS was preferred to conservative CAB treatment or a course of glucocorticoids given the absence of visual function improvement. The optimal management of acute PA is controversial, as some patients recover normal visual and endocrine function after conservative steroid-based management. As prolactinomas with an important bleeding component may not significantly shrink under DA, close surveillance is mandatory for deciding a short trial of glucocorticoids before surgery if DA is ineffective. Surgical decompression is the most rapid treatment to improve symptoms and relieve compression of local structures, particularly the optic pathways (9). UK guidelines for the treatment of PA recommend surgery in case of 'significant neuro-ophthalmic signs or reduced levels of consciousness' (10). Diabetes insipidus occurred in one patient before hormone replacement. At PA onset, diabetes insipidus is rare as it occurs in less than 5% of patients. It may be masked by corticotrophic insufficiency (or secondary hypothyroidism), and may only emerge at the time of steroid (or thyroid hormones) replacement therapy (9).

PA is a rare but serious clinical syndrome with a prevalence of 6.2 cases per 100 000 persons (30). The prevalence of PA in prolactinomas is approximately 6.8% (31), being more frequently observed in macroprolactinomas (20.3%) when compared to microprolactinomas (3.1%). Precipitating factors, such as angiographic procedures (particularly cerebral), surgery (orthopaedic and cardiac), anticoagulant therapy, head trauma, and dynamic endocrine testing or GnRH agonists treatment (9), have been reported. It remains controversial whether DA treatment may induce PA (9), but pregnancy *per se* has been suspected to trigger PA (10, 12, 32). Indeed, pregnancy induces hypertrophy and hyperplasia of lactotroph cells (33). As reviewed by Molitch, the proportion of pregnant patients exhibiting symptomatic microprolactinoma growth is very low (2.4%). By contrast, the prevalence is 21% in macroprolactinomas (34). During pregnancy, the pathogenesis of PA is suggested to include compromised blood supply to the pituitary gland due to the gestational growth of the lactotroph cells and the compression of blood vessels, leading to infarction or haemorrhage (12). Hyperaemia of the pituitary gland due

Table 1 Pituitary apoplexy during pregnancy in patients with prolactinomas (both macroprolactinomas and microprolactinomas). Literature review and report of five new cases of microprolactinomas.

Reference	Age	Parity	Gestation, week	Adenoma size	Previous DA treatment	Presentation			Management	Outcome		
						HA	vs	Endocrine/others		Time, mode of delivery	Nursing	Other
(13)	NR	NR	NR	NR	BRC	Yes	Yes	Endocrine/others	Conservative	LB	NR	NR
(14)	37	NR	8	MA	BRC	Yes	Yes	Vomiting	Surgery	NR	NR	Left-side cranial nerve palsy
(15)	22	1	33	MA	BRC	Yes	Yes	DI	Surgery, HDC, LT4, DES	LB at term	NR	Resolution VFD; persistent DI but no further need for HDC, LT4 or DA
(16)	22	NR	20	MA	BRC	Yes	Yes	NR	Surgery	LB at term	NR	Resolution of visual loss
(11)	31	1	39	NR	BRC	Yes	NR	Nausea	Immediate CS and initiation of BRC	LB at term by CS	NR	NR
(17)	25	NR	14	MA	BRC	Yes	Yes	NR	Surgery (6 weeks after admission for deterioration of neurological condition)	LB at term by CS	NR	NR
(18)	27	1	10	MA	BRC	Yes	Yes	NR	Conservative: BRC 2 x 2.5 mg, LT4, HDC	LB at term by CS	NR	Secondary adrenal insufficiency
(19)	27	NR	36	NR	BRC	Yes	Yes	NR	Surgery	LB at term by CS	NR	Temporary DI
(20)	26	1	28	MA	BRC then CAB	Yes	NR	NR	CAB	LB at term by VD	NR	BRC for 6 months switching to CAB due to lack of improvement: tumour shrinkage after 10 months
(21)	30	1	20	MA	CAB	Yes	NR	NR	CAB from 13th week of gestation until delivery	LB at term by VD	Yes	NR
(22)	30	1	28	MA	None	Yes	Yes	Loss of consciousness	Conservative	LB	Yes	NR
(23)	NR	NR	25	NR	None	Yes	Yes	NR	Surgery	LB	Yes	NR
(23)	NR	NR	NR	MA	UN	Yes	NR	NR	DXM (second trimester)	NR	NR	NR
(24)	22	1	26	MA	CAB	Yes	Yes	nausea	Surgery (8 days after admission)	LB at 37th week	NR	SHT
(25)	NR	NR	NR	MA	CAB	NR	NR	NR	Surgery	NR	NR	NR

Clinical Study			E Kuhn, A A Weinreich and others		Microprolactinoma apoplexy in pregnancy		185:1	105			
(26)	NR 29	NR 1	NR 30	MA MI	BRC BRC	NR Yes NR Yes NR	NR NR	Surgery BRC during 2 weeks and then surgery (VFD in left eye, third cranial nerve palsy in right eye); HDC; LT4 CAB: 0.5 mg/week	NR LB at term by VD	NR NR	NR No further need for HR or DA
(27)	37	1	16	MI	None	Yes Yes NR	Yes Yes NR	Nausea, vomiting	LB at term by CS	NR	NR
(28)	41	1	18	MI	None	Yes Yes NR	Yes Yes NR	Surgery (on admission), high dose corticosteroids	LB at term by VD	NR	No need for HR
(29)	27	1	37	MI	CAB	Yes NR NR	Yes NR NR	Conservative: CAB after child birth	LB at 37th week by CS	Yes	Tumour resolution after 4 months
Current Case reports											
	31	2	36	MI	CAB	Yes Yes Photophobia,	Yes Yes NR	CAB; surgery 2 days after (worsening of visual disturbance)	LB by CS	NR	-
	21	1	~ 24	MI	BRC	No No Fatigue, polyuria-polydipsia	No No NR	Conservative; LT4, HDC, DES; Surgery 5 months after delivery	LB	NR	No further need for HR; DI
	32	3	35	MI	CAB	Yes Yes No	Yes Yes No	CAB; HDC	LB by VD	NR	SAI
	23	1	16	MI	CAB	Yes Yes No	Yes Yes No	CAB	LB at 38th week by CS	Yes	NR
	25	2	~ 24	MI	CAB	Yes No No	Yes No No	Conservative	LB by VD	NR	NR
Total	28 ± 16	1	25 ± 9	MA: 12; MI: 9; UN: 4	BRC: 11; CAB: 8	Headache: 22 (88%); visual disturbance: 16 (64%); nausea: 4 (16%); loss of consciousness: 2 (8%); DI: 1 (4%)	Headache: 22 (88%); visual disturbance: 16 (64%); nausea: 4 (16%); loss of consciousness: 2 (8%); DI: 1 (4%)	Surgery: 12 (48 %); Conservative: 13 (52%); DA: 7; HR: 5	LB: 21 (VD: 8; CS: 7)	Endocrine outcome: 5: (outocrine insufficiency: n = 3; DI: 3 (1 temporary))	

*Data are presented as mean ± s.d., median or n (%). MA, macro; MI, micro; HDC, hydrocortisone; UN, unknown; VFD, visual field defect; DES, desmopressin; LB, live birth; VD, vaginal delivery; SHT, secondary hypothyroidism; SAI, Secondary adrenal insufficiency; HR, hormone replacement; DA, dopamine agonists; BRC, bromocriptine; CAB, cabergoline; HA, Headache; VS, Visual symptoms; DI, Diabetes insipidus; CS, cesarean section; DI, diabetes insipidus; LT4, levothyroxine; DXM, dexamethasone. NR, not reported. BRC, bromocriptine; CAB, cabergoline; CS, caesarean section; DA, dopamine agonists; DES, desmopressin; DI, diabetes insipidus; DXM, dexamethasone; HA, headache; HDC, hydrocortisone; HR, hormone replacement; LB, live birth; LT4, levothyroxine; MA, macro; MI, micro; NR, not reported; SAI, secondary adrenal insufficiency; SHT, secondary hypothyroidism; UN, unknown; VD, vaginal delivery; VFD, visual field defect; VS, visual symptoms.

to oestrogens has been demonstrated in animal models (35). PA is a rare occurrence during pregnancy, with only a few published cases (10, 11, 12). To minimize the risk of PA, it was recommended, in the past, to perform prophylactic debulking surgery of large and treatment-resistant prolactinomas before planned pregnancy (36, 37, 38).

Apoplexy in known prolactinomas during pregnancy is rare and apoplexy in a microprolactinoma during pregnancy is even rarer (only 4 out of the 20 cases reported so far, as detailed in Table 1). We add five cases of microprolactinoma gestational apoplexy to the available literature in the present study. The rationale for reporting these cases originated in the discussion of the ESE guideline committee that the condition of macroprolactinoma apoplexy exists and that awareness and a better registration of cases are of interest to the community. Before pregnancy, adenoma size was available only in 21 out of the 25 cases, 12 of them were diagnosed as macroadenomas and 9 as microadenomas. In all cases, DAs were discontinued at the diagnosis of pregnancy. For gestational macroprolactinomas, the clinical guidelines (36, 37, 38) recommend at least visual field testing at each trimester of pregnancy or more frequently according to the tumour size. MRI without gadolinium is recommended in case of visual field change and/or the occurrence of severe headache. As microprolactinomas rarely increase in size, a routine MRI and visual field testing during pregnancy are not recommended. Indeed, the risk of asymptomatic tumour growth is 4.5% (39) and that of symptomatic tumour growth is <2% (40). The risk of development of new neurological sequelae (headaches, optic nerve compression, etc.) ranges from 1.6 to 5.5% (41). PRL serum levels tend to increase during pregnancy; therefore, they do not reliably reflect an increase in tumour size and PRL measurement is thus not useful for clinical assessment. The common denominator of our cases (as in other cases reported in the literature) is that the growth of microprolactinomas during pregnancy was symptomatic and attributed to PA.

PA of prolactinomas during pregnancy mostly occurred during the second or third trimester (only two cases of PA were observed during the first trimester of pregnancy). The main presenting symptom was a sudden severe headache, followed by visual disturbances (16 cases including 6 microprolactinomas). Thus, a headache is a presenting symptom that patients and physicians should be aware of, even in cases with microprolactinoma. In case of intractable headache or visual symptoms, MRI without contrast and endocrine function tests to exclude deficits

are advised. Cases of asymptomatic haemorrhage during pregnancy diagnosed on postpartum imaging have been reported (42). This could be one of the explanations for the decreased serum prolactin level often observed after DA-induced pregnancy, as compared to pregestational prolactin level (42, 43).

Most of the patients were able to deliver healthy babies at normal terms.

The optimal management of PA, in general, is still controversial (surgery vs conservative approach) and requires a multidisciplinary team, including an endocrinologist, neuroradiologist, ophthalmologist and neurosurgeon (10). The aims of the treatment are to improve symptoms and relieve compression of local structures (optic pathways). UK guidelines for the treatment of PA recommend surgery in case of 'significant neuro-ophthalmic signs or reduced levels of consciousness' (10). If surgery is decided, its timing is important. Indeed, the prognosis of visual defects is less favourable when surgery takes place more than 1 week after onset (44), whereas there seems to be no difference in outcome when surgery is performed either during the first 3 days or the first week after symptom onset (9). In the literature (including our case reports), surgery was performed during pregnancy in 12 cases (48%). The exact time of the surgery was not given in seven cases, but in three cases, surgery was performed within days of admission (<8 days). In one case, the surgery was performed after 2 weeks of bromocriptine treatment for emerging visual disturbances, and in another case, the surgery was performed 6 weeks after admission for neurological deterioration. The other half of the cases were managed conservatively, with DA therapy in seven cases and hormone replacement when necessary. Outside of pregnancy, conservative treatment is an alternative strategy in selected patients without visual loss, as suggested by reports of spontaneous clinical improvement and tumour shrinkage (45, 46, 47, 48, 49). Whatever the treatment approach, visual symptoms recovered well. Among the four prolactinoma pregnant patients with endocrine deficiencies at diagnosis of PA, only one recovered normal pituitary function: she was initially treated conservatively during 2 weeks and then pituitary surgery was performed. In general, the two approaches (surgery vs conservative treatment) in the case of PA seem to have the same impact on functional pituitary recovery (9, 50). During pregnancy, it is inherently difficult to provide evidence-based guidance as regards the management of PA. PA during pregnancy mainly occurs in the third trimester, and it is generally recommended to delay any surgery until after 30 gestational weeks to optimize

foetus survival (51). Moreover, an effective medical treatment with DA is available for prolactinomas which may argue for proposing, at least in the first intention, a watchful attitude associated with DA treatment in case of prolactinoma apoplexy during pregnancy, particularly for microprolactinomas where reinstatement of DA at low dose is often sufficient to control pain and tumour volume in the majority of cases. If DA fails to improve headache or visual problems, surgical removal will be indicated. This is in line with the ESE clinical practice guideline (Luger *et al.* Personal communication).

Thus, patients should be managed on a case-by-case basis, depending on the severity of symptoms at presentation, progression of the disease and surgical expertise available, taking into account the risks for the mother and the risk of surgery for the baby.

Conclusion

Symptomatic PA of a prolactinoma during pregnancy is a rare condition that has been reported in 25 patients to date, including 9 patients with microprolactinomas. Although the rarity of this event is reassuring, physicians managing pregnant women with pituitary adenomas, including microprolactinomas, must be aware that PA may occur.

Declaration of interest

The authors declare that there is no conflict of interest that could be perceived as prejudicing the impartiality of this study.

Funding

This research did not receive any specific grant from any funding agency in the public, commercial or not-for-profit sector.

Author contribution statement

N R Biermasz, J O L Jorgensen and P Chanson have contributed equally.

References

- Molitch ME. Pituitary tumours: pituitary incidentalomas. *Best Practice and Research: Clinical Endocrinology and Metabolism* 2009 **23** 667–675. (<https://doi.org/10.1016/j.beem.2009.05.001>)
- Chanson P & Maiter D. The epidemiology, diagnosis and treatment of prolactinomas: the old and the new. *Best Practice and Research: Clinical Endocrinology and Metabolism* 2019 **33** 101290. (<https://doi.org/10.1016/j.beem.2019.101290>)
- Lamba N, Noormohamed N, Simjian T, Alsheikh MY, Jamal A, Doucette J, Zaidi H, Smith TR & Mekary RA. Fertility after transsphenoidal surgery in patients with prolactinomas: a meta-analysis. *Clinical Neurology and Neurosurgery* 2019 **176** 53–60. (<https://doi.org/10.1016/j.clineuro.2018.11.024>)
- Touraine P, Plu-Bureau G, Beji C, Mauvais-Jarvis P & Kuttent F. Long-term follow-up of 246 hyperprolactinemic patients. *Acta Obstetrica et Gynecologica Scandinavica* 2001 **80** 162–168. (<https://doi.org/10.1034/j.1600-0412.2001.080002162.x>)
- Berinder K, Stackenäs I, Akre O, Hirschberg AL & Hulting AL. Hyperprolactinaemia in 271 women: up to three decades of clinical follow-up. *Clinical Endocrinology* 2005 **63** 450–455. (<https://doi.org/10.1111/j.1365-2265.2005.02364.x>)
- Wong A, Eloy JA, Couldwell WT & Liu JK. Update on prolactinomas. Part 1: Clinical manifestations and diagnostic challenges. *Journal of Clinical Neuroscience* 2015 **22** 1562–1567. (<https://doi.org/10.1016/j.jocn.2015.03.058>)
- Gillam MP, Molitch ME, Lombardi G & Colao A. Advances in the treatment of prolactinomas. *Endocrine Reviews* 2006 **27** 485–534. (<https://doi.org/10.1210/er.2005-9998>)
- Schlechte J, Dolan K, Sherman B, Chapler F & Luciano A. The natural history of untreated hyperprolactinemia: a prospective analysis. *Journal of Clinical Endocrinology and Metabolism* 1989 **68** 412–418. (<https://doi.org/10.1210/jcem-68-2-412>)
- Briet C, Salenave S, Bonneville JF, Laws ER & Chanson P. Pituitary apoplexy. *Endocrine Reviews* 2015 **36** 622–645. (<https://doi.org/10.1210/er.2015-1042>)
- Rajasekaran S, Vanderpump M, Baldeweg S, Drake W, Reddy N, Lanyon M, Markey A, Plant G, Powell M, Sinha S *et al.* UK guidelines for the management of pituitary apoplexy. *Clinical Endocrinology* 2011 **74** 9–20. (<https://doi.org/10.1111/j.1365-2265.2010.03913.x>)
- Ginath S & Golan A. Images in clinical medicine. Gestational pituitary-tumor apoplexy. *New England Journal of Medicine* 2010 **363** e10. (<https://doi.org/10.1056/NEJMicm0900500>)
- de Heide LJM, van Tol KM & Doornbos B. Pituitary apoplexy presenting during pregnancy. *Netherlands Journal of Medicine* 2004 **62** 393–396.
- Lamberts SW, Klijn JG, de Lange SA, Singh R, Stefanko SZ & Birkenhäger JC. The incidence of complications during pregnancy after treatment of hyperprolactinemia with bromocriptine in patients with radiologically evident pituitary tumors. *Fertility and Sterility* 1979 **31** 614–619. ([https://doi.org/10.1016/s0015-0282\(16\)44050-1](https://doi.org/10.1016/s0015-0282(16)44050-1))
- O'Donovan PA, O'Donovan PJ, Ritchie EH, Feely M & Jenkins DM. Apoplexy into a prolactin secreting macroadenoma during early pregnancy with successful outcome. Case report. *British Journal of Obstetrics and Gynaecology* 1986 **93** 389–391.
- Freeman R, Wezenter B, Silverstein M, Kuo D, Weiss KL, Kantrowitz AB & Schubart UK. Pregnancy-associated subacute hemorrhage into a prolactinoma resulting in diabetes insipidus. *Fertility and Sterility* 1992 **58** 427–429. ([https://doi.org/10.1016/s0015-0282\(16\)55219-4](https://doi.org/10.1016/s0015-0282(16)55219-4))
- Parihar V, Yadav YR & Sharma D. Pituitary apoplexy in a pregnant woman. *Annals of Indian Academy of Neurology* 2009 **12** 54–55. (<https://doi.org/10.4103/0972-2327.48861>)
- Witek P, Zieliński G, Maksymowicz M & Zgliczyński W. Transsphenoidal surgery for a life-threatening prolactinoma apoplexy during pregnancy. *Neuro Endocrinology Letters* 2012 **33** 483–488.
- Janssen NM, Dreyer K & van der Weiden RMF. Management of pituitary tumour apoplexy with bromocriptine in pregnancy. *JRSM Short Reports* 2012 **3** 43. (<https://doi.org/10.1258/shorts.2012.011144>)
- Tandon A, Alzate J, LaSala P & Fried MP. Endoscopic endonasal transsphenoidal resection for pituitary apoplexy during the third trimester of pregnancy. *Surgery Research and Practice* 2014 **2014** 397131. (<https://doi.org/10.1155/2014/397131>)
- De Ycaza AE, Chang AY, Jensen JR, Khan Z & Erickson D. Approach to the management of rare clinical presentations of macroprolactinomas in reproductive-aged women. *Case Reports in Women's Health* 2015 **8** 9–12. (<https://doi.org/10.1016/j.crwh.2015.09.001>)

- 21 Grand'Maison S, Weber F, Bédard MJ, Mahone M & Godbout A. Pituitary apoplexy in pregnancy: a case series and literature review. *Obstetric Medicine* 2015 **8** 177–183. (<https://doi.org/10.1177/1753495X15598917>)
- 22 Galvão A, Gonçalves D, Moreira M, Inocência G, Silva C & Braga J. Prolactinoma and pregnancy – a series of cases including pituitary apoplexy. *Journal of Obstetrics and Gynaecology* 2017 **37** 284–287. (<https://doi.org/10.1080/01443615.2016.1233946>)
- 23 Lambert K, Rees K, Seed PT, Dhanjal MK, Knight M, McCance DR & Williamson C. Macroprolactinomas and nonfunctioning pituitary adenomas and pregnancy outcomes. *Obstetrics and Gynecology* 2017 **129** 185–194. (<https://doi.org/10.1097/AOG.0000000000001747>)
- 24 Oguz SH, Soylemezoglu F, Dagdelen S & Erbas T. A case of atypical macroprolactinoma presenting with pituitary apoplexy during pregnancy and review of the literature. *Gynecological Endocrinology* 2020 **36** 109–116. (<https://doi.org/10.1080/09513590.2019.1650339>)
- 25 Sant' Anna BG, Musolino NRC, Gadelha MR, Marques C, Castro M, Elias PCL, Vilar L, Lyra R, Martins MRA, Quidute ARP et al. A Brazilian multicentre study evaluating pregnancies induced by cabergoline in patients harboring prolactinomas. *Pituitary* 2020 **23** 120–128. (<https://doi.org/10.1007/s11102-019-01008-z>)
- 26 Gondim J, Ramos Júnior F, Pinheiro I, Schops M & Tella Júnior OI. Minimally invasive pituitary surgery in a hemorrhagic necrosis of adenoma during pregnancy. *Minimally Invasive Neurosurgery* 2003 **46** 173–176. (<https://doi.org/10.1055/s-2003-40734>)
- 27 Couture N, Aris-Jilwan N & Serri O. Apoplexy of a microprolactinoma during pregnancy: case report and review of literature. *Endocrine Practice* 2012 **18** e147–e150. (<https://doi.org/10.4158/EP12106.CR>)
- 28 Hayes AR, O'Sullivan AJ & Davies MA. A case of pituitary apoplexy in pregnancy. *Endocrinology, Diabetes and Metabolism Case Reports* 2014 **2014** 140043. (<https://doi.org/10.1530/EDM-14-0043>)
- 29 Annamalai AK, Jeyachitra G, Jeyamithra A, Ganeshkumar M, Srinivasan KG & Gurnell M. Gestational pituitary apoplexy. *Indian Journal of Endocrinology and Metabolism* 2017 **21** 484–485. (https://doi.org/10.4103/ijem.IJEM_8_17)
- 30 Fernandez A, Karavitaki N & Wass JAH. Prevalence of pituitary adenomas: a community-based, cross-sectional study in Banbury (Oxfordshire, UK). *Clinical Endocrinology* 2010 **72** 377–382. (<https://doi.org/10.1111/j.1365-2265.2009.03667.x>)
- 31 Sarwar KN, Huda MSB, Van de Velde V, Hopkins L, Luck S, Preston R, McGowan BM, Carroll PV & Powrie JK. The prevalence and natural history of pituitary hemorrhage in prolactinoma. *Journal of Clinical Endocrinology and Metabolism* 2013 **98** 2362–2367. (<https://doi.org/10.1210/jc.2013-1249>)
- 32 Semple PL, Jane JA & Laws ER. Clinical relevance of precipitating factors in pituitary apoplexy. *Neurosurgery* 2007 **61** 956–961; discussion 961–962. (<https://doi.org/10.1227/01.neu.0000303191.57178.2a>)
- 33 Molitch ME. Pituitary tumors and pregnancy. *Growth Hormone and IGF Research* 2003 **13** (Supplement A) S38–S44. ([https://doi.org/10.1016/s1096-6374\(03\)00054-6](https://doi.org/10.1016/s1096-6374(03)00054-6))
- 34 Molitch ME. Endocrinology in pregnancy: management of the pregnant patient with a prolactinoma. *European Journal of Endocrinology* 2015 **172** R205–R213. (<https://doi.org/10.1530/EJE-14-0848>)
- 35 Dinç H, Esen F, Demirci A, Sari A & Resit Gümele H. Pituitary dimensions and volume measurements in pregnancy and post partum. MR assessment. *Acta Radiologica* 1998 **39** 64–69. (<https://doi.org/10.1080/02841859809172152>)
- 36 Melmed S, Casanueva FF, Hoffman AR, Kleinberg DL, Montori VM, Schlechte JA, Wass JAH & Endocrine Society. Diagnosis and treatment of hyperprolactinemia: an Endocrine Society clinical practice guideline. *Journal of Clinical Endocrinology and Metabolism* 2011 **96** 273–288. (<https://doi.org/10.1210/jc.2010-1692>)
- 37 Casanueva FF, Molitch ME, Schlechte JA, Abs R, Bonert V, Bronstein MD, Brue T, Cappabianca P, Colao A, Fahlbusch R et al. Guidelines of the Pituitary Society for the diagnosis and management of prolactinomas. *Clinical Endocrinology* 2006 **65** 265–273. (<https://doi.org/10.1111/j.1365-2265.2006.02562.x>)
- 38 Maiter D & Primeau V. 2012 Update in the treatment of prolactinomas. *Annales d'Endocrinologie* 2012 **73** 90–98. (<https://doi.org/10.1016/j.ando.2012.03.024>)
- 39 Molitch ME. Pregnancy and the hyperprolactinemic woman. *New England Journal of Medicine* 1985 **312** 1364–1370. (<https://doi.org/10.1056/NEJM198505233122106>)
- 40 Kupersmith MJ, Rosenberg C & Kleinberg D. Visual loss in pregnant women with pituitary adenomas. *Annals of Internal Medicine* 1994 **121** 473–477. (<https://doi.org/10.7326/0003-4819-121-7-199410010-00001>)
- 41 Gemzell C & Wang CF. Outcome of pregnancy in women with pituitary adenoma. *Fertility and Sterility* 1979 **31** 363–372. ([https://doi.org/10.1016/s0015-0282\(16\)43929-4](https://doi.org/10.1016/s0015-0282(16)43929-4))
- 42 Bronstein MD. Prolactinomas and pregnancy. *Pituitary* 2005 **8** 31–38. (<https://doi.org/10.1007/s11102-005-5083-4>)
- 43 Bergh T, Nillius SJ & Wide L. Clinical course and outcome of pregnancies in amenorrhoeic women with hyperprolactinaemia and pituitary tumors. *BMJ* 1978 **1** 875–880. (<https://doi.org/10.1136/bmj.1.6117.875>)
- 44 Randeve HS, Schoebel J, Byrne J, Esiri M, Adams CB & Wass JA. Classical pituitary apoplexy: clinical features, management and outcome. *Clinical Endocrinology* 1999 **51** 181–188. (<https://doi.org/10.1046/j.1365-2265.1999.00754.x>)
- 45 Ayuk J, Clayton RN, Holder G, Sheppard MC, Stewart PM & Bates AS. Growth hormone and pituitary radiotherapy, but not serum insulin-like growth factor-I concentrations, predict excess mortality in patients with acromegaly. *Journal of Clinical Endocrinology and Metabolism* 2004 **89** 1613–1617. (<https://doi.org/10.1210/jc.2003-031584>)
- 46 Pelkonen R, Kuusisto A, Salmi J, Eistola P, Raitta C, Karonen SL & Aro A. Pituitary function after pituitary apoplexy. *American Journal of Medicine* 1978 **65** 773–778. ([https://doi.org/10.1016/0002-9343\(78\)90795-7](https://doi.org/10.1016/0002-9343(78)90795-7))
- 47 Jeffcoate WJ & Birch CR. Apoplexy in small pituitary tumours. *Journal of Neurology, Neurosurgery, and Psychiatry* 1986 **49** 1077–1078. (<https://doi.org/10.1136/jnnp.49.9.1077>)
- 48 McFadzean RM, Doyle D, Rampling R, Teasdale E & Teasdale G. Pituitary apoplexy and its effect on vision. *Neurosurgery* 1991 **29** 669–675. (<https://doi.org/10.1097/00006123-199111000-00005>)
- 49 Maccagnan P, Macedo CL, Kayath MJ, Nogueira RG & Abucham J. Conservative management of pituitary apoplexy: a prospective study. *Journal of Clinical Endocrinology and Metabolism* 1995 **80** 2190–2197. (<https://doi.org/10.1210/jcem.80.7.7608278>)
- 50 Giritharan S, Gnanalingham K & Kearney T. Pituitary apoplexy – bespoke patient management allows good clinical outcome. *Clinical Endocrinology* 2016 **85** 415–422. (<https://doi.org/10.1111/cen.13075>)
- 51 Gaillon T, Cuny T, Castinetti F, Courbière B, Cousin M, Albarel F, Morange I, Bruder N, Brue T & Dufour H. Surgical indications for pituitary tumors during pregnancy: a literature review. *Pituitary* 2020 **23** 189–199. (<https://doi.org/10.1007/s11102-019-01004-3>)

Received 6 February 2021

Revised version received 13 April 2021

Accepted 29 April 2021